

## TO EVALUATE THE EFFECT OF ADDING CLONIDINE TO ROPIVACAINE IN ULTRASOUND GUIDED INFRACLAVICULAR BRACHIAL PLEXUS BLOCK IN UPPER LIMB SURGERIES

Pyarejan Basheer<sup>1</sup>, Hassaan Muhammed<sup>1</sup>, Swathy S Iyengar<sup>2</sup>, Khutejatul Kubra<sup>3</sup>, Praveen Raja KR<sup>4</sup>

Received : 05/05/2023  
Received in revised form : 13/06/2023  
Accepted : 27/06/2023

**Keywords:**  
Infraclavicular Brachial plexus;  
Ropivacaine; Clonidine.

Corresponding Author:  
**Dr. Hassaan Muhammed,**  
Email: hassaandr@gmail.com

DOI: 10.47009/jamp.2023.5.4.38

Source of Support: Nil,  
Conflict of Interest: None declared

*Int J Acad Med Pharm*  
2023; 5 (4); 180-184



<sup>1</sup>Assistant Professor, Department of Anaesthesiology, PES Institute of Medical Sciences and Research, Kuppam, Andhra Pradesh, India.

<sup>2</sup>Consultant Neuroanaesthesiologist, People Tree Institute of Neurosciences, Bengaluru, Karnataka, India.

<sup>3</sup>Resident Anaesthesiologist, Cauvery Heart and Multi-Speciality Hospital, Mysore, Karnataka, India.

<sup>4</sup>Specialist Anaesthesiologist, Hope hospital, Bengaluru, Karnataka, India.

### Abstract

**Background:** To study the duration of postoperative analgesia. **Materials and Methods:** A randomised prospective placebo controlled double blind study was undertaken in patients posted for upper limb surgeries under ultrasound guided infraclavicular brachial plexus block. 60 patients with ASA I & II were randomly grouped into two groups. Group R received 20ml of 0.5% ropivacaine mixed with 1.5ml of (0.9%) saline (placebo) and Group C received 20ml of 0.5% ropivacaine with 1.5ml of clonidine 150mcg. **Result:** Group C by adding Clonidine to Ropivacaine has a quicker onset of the sensory ( $12.57 \pm 3.22$ mins) and motor blockade ( $25.1 \pm 5.89$ mins), increased duration of postoperative analgesia ( $12.27 \pm 1.17$ hrs), prolongs the time for the requirement for rescue analgesia ( $12.78 \pm 0.85$ hrs) and reduces the dose for rescue analgesia ( $34.78 \pm 12.48$ mcg) significantly. **Conclusion:** A combination of ropivacaine 0.5% and clonidine 150mcg has a significantly faster onset of sensory and motor blockade and prolonged duration of postoperative analgesia.

## INTRODUCTION

Brachial plexus block provides a useful alternative to general anaesthesia for upper limb surgeries by achieving ideal operating conditions with adequate muscular relaxation, maintaining stable hemodynamics intraoperatively, and sympathetic block. It is gaining popularity over general anaesthesia due to its effectiveness in terms of cost, performance and good postoperative profile. The infraclavicular block is a method of accomplishing brachial plexus anaesthesia and is well suited for hand, wrist, elbow and distal arm surgery. It also provides excellent analgesia for an arm tourniquet.<sup>[1]</sup> By providing precise control of needle placement, ultrasound may improve the success rate of the block and minimise the vascular and neurological complications.<sup>[2]</sup> Ropivacaine having lower lipid solubility has produced less central nervous system toxicity and cardiotoxicity than bupivacaine for which it is gaining popularity over bupivacaine for peripheral nerve blocks.<sup>[3]</sup> Adjuvants like Neostigmine, Opioids, Hyaluronidase, Midazolam, Clonidine, Dexamethasone, etc., have been added to local anaesthetics to improve the quality and duration

of action and postoperative analgesia.<sup>[4]</sup> Previous studies have shown the effect of adding Clonidine to Ropivacaine in supraclavicular brachial plexus block in prolonging analgesia and motor blockade significantly.<sup>[5]</sup> Whereas few studies have evaluated the effect of adding Clonidine to Ropivacaine in Infraclavicular Brachial Plexus blocks.

## MATERIALS AND METHODS

This randomised prospective placebo controlled double blind study was conducted on 60 patients undergoing upper limb surgeries under Ultra Sound Guided Infraclavicular Brachial Plexus Block at a Medical College hospital, from 1<sup>st</sup> January 2015 to 31<sup>st</sup> December 2016. Ethical clearance was obtained before the institutional ethical review committee. Informed, bilingual, and written consent was obtained from all the patients. Patients between the age group of 18-60 years under ASA1 and ASA2 were included in the study. Patients' refusal for nerve block and patients having severe lung disease, contralateral diaphragmatic paralysis, pre-existing neuropathy involving the surgical limb, coagulopathy, pregnancy, patients on anticoagulation

therapy, severe anaemia, hypovolemia, shock, septicaemia, local infection at the site of block, known allergy to local anaesthetic drugs were excluded from the study. The patients were randomized into two groups of 30 each by using the "slips in the box technique" and assigned as Group R and Group C. Patients in Group R received 20ml of Ropivacaine (0.5%) and 1.5 ml of Normal saline, Group C received 20ml of Ropivacaine (0.5%) and 1.5 ml clonidine(100mcg/ml).

Block was performed using strict aseptic precautions under Ultrasound guidance (SonoSite M-Turbo with a curvilinear array transducer) in a randomized double-blind fashion in 60 patients of both sexes. A 22 G short beveled 10 cm needle was used for the study. Demographic (age, gender, comorbidities) and Morphometric (height, weight) characteristics of participating patients were recorded. Patients fasted overnight. An 18G IV line was secured and patients were connected to monitors to record pulse, O<sub>2</sub> saturation, NIBP, and ECG. Premedication with Inj. Midazolam 1mg and Inj. Glycopyrrolate 0.2 mg was given before the procedure. The patient in supine position, arms by the side and head turned to the other side. An anaesthetist not involved in the study was asked to give the block. After incremental injection of the local anaesthetic mixture, patients were evaluated at 5 min intervals for 30 mins for developing the sensory and motor block. In the case of inadequate blockade, the case was converted to general anaesthesia and was not considered in the study. The severity of postoperative pain was assessed by using a verbal response score (VRS). Patients reporting severe pain were given intravenous Fentanyl (1 mcg/kg body weight) repeated till comfortable. The time of onset for the sensory blockade, defined as the time between injection of local anaesthetic and abolition of pinprick response was evaluated in four nerve areas (radial, ulnar, median, musculocutaneous) every 5 mins until 30 mins after the injection. The block was judged failed if anaesthesia was not present in 2 or more peripheral nerve distributions and such patients were excluded from the study. For motor block, the inability to flex or extend the following joints: musculocutaneous nerve (flex elbow), median nerve (flex distal interphalangeal joint of 2nd finger), radial nerve (extend wrist), ulnar nerve (abduct 3rd and 4th fingers) was tested. The time of onset of motor block, defined as the time between injection of local anaesthetic and inability to move the joints was evaluated every 5 mins, and time to block at least 2 major nerves was noted. The duration of sensory blockade, defined as the time between onset of action and return of pinprick response, was assessed every 60 minutes in at least 3 major nerve territories. The duration of analgesia, defined as the time between the onset of action and the onset of pain, was the time when the patients received the first dose of rescue analgesic. The duration of motor blockade was assessed every 60 mins till the return of complete muscle power in at least 2 major nerve distributions.

The pain was assessed by standardized verbal response score (VRS) at 0, 1, 3, 6, 9, 12, and 24 hours postoperatively. A VRS score of more than 3 was considered inadequate analgesia. The time to the first dose of rescue analgesia and the total amount of fentanyl required in the first 24 hours postoperatively was noted.

Descriptive and inferential statistical analysis was carried out in the study. Results on continuous measurements were presented on Mean  $\pm$  SD (Min-Max) and results on categorical measurements in Number (%). Significance was assessed at a 5% level of significance. Student "t" test (two-tailed, independent) was used to find the significance of study parameters on a continuous scale between two groups (Intergroup analysis). Chi-square/ Fisher Exact test was used to find the significance of study parameters on a categorical scale between two or more groups. Significant figure: Suggestive significance (p-value:  $0.05 < p < 0.10$ ). Moderately significant (p-value:  $0.01 < p < 0.05$ ). Strongly significant (p-value:  $p < 0.01$ ). The Statistical software namely SAS 9.2, SPSS 15.0, Stata 10.1, MedCalc 9.0.1, Systat 12.0, and R environment ver.2.11.1 was used for the analysis of the data.

## RESULTS

This randomized prospective controlled double-blind study was conducted in 60 patients of either gender of ASA physical status I/II in the age group of 18-60 years scheduled for elective upper limb surgeries of arm, forearm, and hand under Ultrasound Guided Infraclavicular Brachial plexus block comparing Ropivacaine 0.5% and Ropivacaine 0.5% with Clonidine 150mcg.

The majority of patients were in the age group of 25-50 years. The mean age of patients who received ropivacaine were  $40.03 \pm 10.54$  years and those who received ropivacaine with clonidine were  $35.9 \pm 10.12$  years. The distribution of patients with respect to age was comparable in both the groups (p-value 0.127). Patients of either gender were randomly selected. Group R had 7 female and 23 male patients whereas Group C had 2 female patients and 28 male patients.

Considering the type of surgery In Group R, the percentage of cases of Carpal tunnel release was 13%, Excision & Biopsy 13%, Implant removal 13%, K-wire fixation 10 %, ORIF with Plate 33%, Post burn contracture Release 3% and Wound debridement 13%. In Group C, the percentage of cases of Carpal tunnel release was 7%, Excision & Biopsy 3%, Implant removal was 13%, K-wire fixation 17 %, ORIF with Plate 33%, Post burn contracture Release 13% and Wound debridement 13% [Figure 1].

The mean time of onset of sensory block in Group C was  $5.30 \pm 1.02$ mins and  $10.83 \pm 1.05$ mins in Group R. The mean time of onset of motor block in Group C was  $7.87 \pm 1.33$  mins and in Group R was  $13.87 \pm$

1.33 mins. The time of onset of both sensory and motor block was significantly faster in Group C ( $p < 0.001$ ). [Figure 2 & Table 1].

The mean heart rate in Group R was around 82 to 92 beats per minute. The mean heart rate in Group C was around 81 to 91 beats per minute. There was no statistically significant difference between the two groups in heart rate at different time intervals [Figure 3].

The mean systolic and diastolic pressure in Group R was  $142.17 \pm 8.7$  mm of Hg and  $93.63 \pm 7.39$  mm of Hg respectively. It was  $144.93 \pm 12.27$  mm of Hg and  $92.67 \pm 8.44$  mm of Hg in Group C respectively at different time intervals. There was no statistically significant difference in systolic blood pressure and diastolic blood pressure between the two groups at different time intervals [Figure 4-5].

The primary objective of this study was to evaluate the postoperative analgesia in both the groups. The patients in Group R first complained of pain at  $9.07 \pm 0.83$  hours and the patients in Group C complained of pain at  $12.27 \pm 1.17$  hours, which was very significant. The first time of rescue analgesia and the total dose of rescue analgesia required by Group R was  $10.10 \pm 0.80$  hours and  $65.83 \pm 27.45$  mcg respectively, whereas the first time of rescue analgesic given was at  $12.78 \pm 0.85$  hours and the total dose of fentanyl used was  $34.78 \pm 12.48$  mcg in Group C. These values were statistically very significant. We infer those patients receiving only ropivacaine required rescue analgesic earlier and in larger quantities whereas those receiving ropivacaine with clonidine were much later and lesser [Figure 6 & Table 2].

When comparing the pain score in the two groups, Group R had moderate to severe pain while Group C had no pain to moderate pain in the first 24 hours postoperatively. This study showed by adding clonidine to ropivacaine improves postoperative pain relief in patients significantly [Figure 7 & Table 3]. Since the hemodynamic responses were similar, the study showed ropivacaine-clonidine combination is also safer to use in brachial plexus block. No such adverse effects were reported in either of the groups in this study.

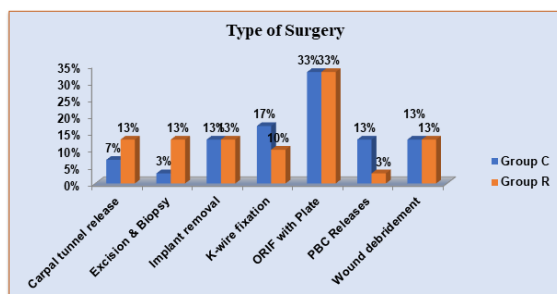


Figure 1: Type of Surgery

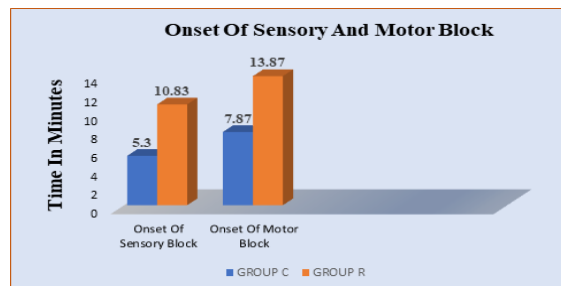


Figure 2: Onset of Sensory and Motor Block

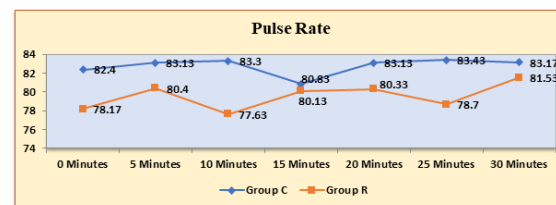


Figure 3: Pulse Rate

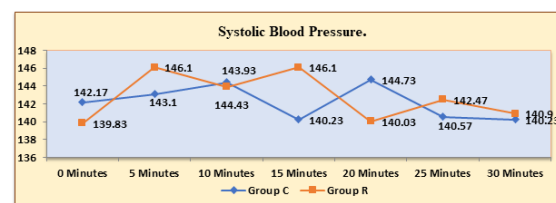


Figure 4: Systolic Blood Pressure.

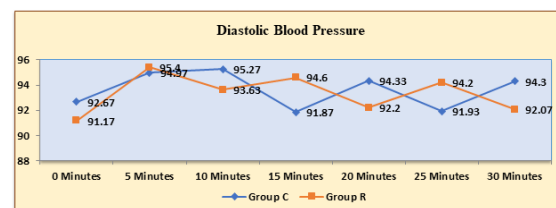


Figure 5: Diastolic Blood Pressure.

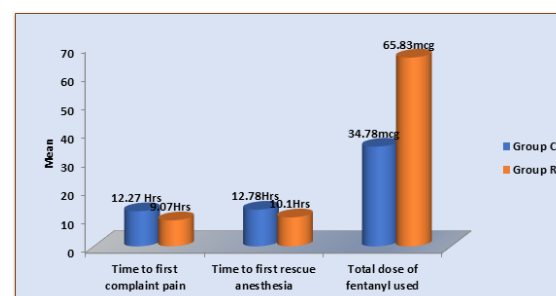


Figure 6: Time to First complain of pain / Time to first rescue analgesia / Total dose of fentanyl used.

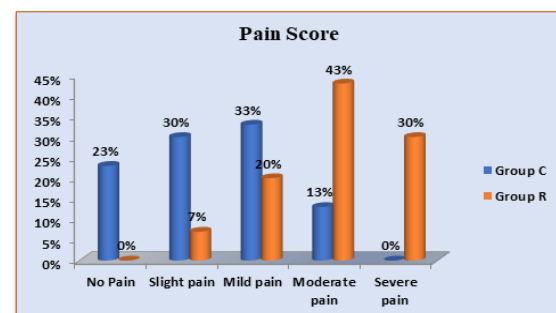


Figure 7: Pain Score

**Table 1: Onset of Sensory & Motor Block**

	Group C	Group R	p value
Onset of sensory block (mins)	5.30 ± 1.02	10.83 ± 1.05	<0.001 HS
Onset of motor block (mins)	7.87 ± 1.33	13.87 ± 1.33	<0.001 HS

**Table 2: Time to First complain of pain / Time to first rescue analgesia / Total dose of fentanyl used**

	Group C	Group R	p value
Time to first complaint pain (hrs)	12.27 ± 1.17	9.07 ± 0.83	<0.001 HS
Time of first rescue analgesia (hrs)	12.78 ± 0.85	10.10 ± 0.80	<0.001 HS
Total dose of fentanyl used (mcg)	34.78 ± 12.48	65.83 ± 27.45	<0.001 HS

**Table 3: Pain Score**

Pain score	Group C (n=30)	Group R (n=30)
No Pain	7 (23%)	0
Slight pain	9 (30%)	2 (7%)
Mild pain	10 (33%)	6 (20%)
Moderate pain	4 (13%)	13 (43%)
Severe pain	0	9 (30%)

p<0.001\*\*, Significant, Chi Square test

## DISCUSSION

A brachial plexus block is appropriate for surgery of the upper limb. An infraclavicular block is indicated for surgery of the forearm, wrist, and hand because it is possible to cover all sensory territories of the distal part of the upper limb with only one puncture. It has recently become a technique of increasing interest.<sup>[6]</sup> This technique is often used to provide not only anaesthesia but also post-operative analgesia for limb surgeries. Brachial plexus block offers many advantages over general anaesthesia for upper limb surgeries such as sympathetic block, better post-operative analgesia, and fewer side effects.<sup>[7]</sup> The advantages of the infraclavicular approach in brachial plexus block are that it causes less discomfort to the patient as the positioning of the arm is not required and there is a lower incidence of pneumothorax.<sup>[8]</sup> Ultrasound guided infraclavicular approach to the brachial plexus is an emerging technique. It helps in the visualisation of the deposition of drugs over cords and branches of the brachial plexus above the formation of musculocutaneous and axillary nerves. This approach can also easily block the ulnar segment of the medial cord and intercostobrachial nerve, which helps prevent tourniquet pain.<sup>[9]</sup> Local anaesthetic ropivacaine is less lipophilic than bupivacaine hence less central nervous system toxicity and cardiotoxicity. It has been used alone and with other adjuvants in numerous other blocks. This study was done to examine the effect of adding clonidine to ropivacaine in Ultrasound guided infraclavicular brachial plexus block. This study was done to detect a modest interaction between clonidine and ropivacaine: an interaction that proved to be both statistically significant and clinically important. However, the studies are scant to evaluate the efficacy of ropivacaine alone and when used in combination with clonidine in Infraclavicular brachial plexus block. Hence, this study was undertaken to evaluate its efficacy of it. A randomized double-blinded study was taken up among 60 patients posted for upper limb surgeries

under ultrasound guided infraclavicular brachial plexus block who were aged between 20 to 60 years. The mean age of patients posted was 40.03 ± 10.54 years in ropivacaine and 35.9 ± 10.12 years in ropivacaine-clonidine groups. There was no statistically significant difference in age between the two groups. Hence, the two groups were comparable in the aspect of age. The majority of the patients in this study belonged to 25-50 years in both groups. The mean time of onset of sensory block in the ropivacaine group was 13.40 ± 3.90 minutes, which was longer as compared to the ropivacaine-clonidine group, 12.57 ± 3.22 minutes. The mean onset of motor block in the ropivacaine group was 25.9 ± 7.11 minutes, which was also longer as compared to the ropivacaine-clonidine group which was of 25.1 ± 5.89 minutes. In a study done by Usha Bafna et al,<sup>[10]</sup> who compared ropivacaine plain with ropivacaine-clonidine. The mean onset of action was 11.4±3.4 minutes with ropivacaine plain while it was 10.18±2.48 ropivacaine-clonidine. In our study adding clonidine as an adjuvant to local anaesthetic ropivacaine, it reduced the time of onset of motor and sensory block. However, we did not find any study about the effect of adding clonidine to ropivacaine in the infraclavicular brachial plexus block. In this study, the mean time of the first complaint of pain with ropivacaine-clonidine was 12.27 ± 1.17 hours, and with ropivacaine alone was 9.07 ± 0.83 hours. The mean number of rescue analgesic doses of intravenous fentanyl were 34.78 ± 12.48mcg in the ropivacaine-clonidine group and in the ropivacaine alone group it was 65.83 ± 27.45mcg. In a study done by Usha Bafna et al,<sup>[10]</sup> Clonidine 2µg/kg body weight when added to 0.5% ropivacaine in supraclavicular brachial plexus block significantly prolonged sensory and motor block and provides better postoperative analgesia. There was no statistically significant difference between the pulse rates of the ropivacaine-clonidine group than ropivacaine group. But it was within normal limits. The mean systolic and diastolic

pressure was also almost similar in both groups and within normal limits.

In summary, the hemodynamic responses are crucial in the maintenance of patient during anaesthesia. However, ropivacaine has already proved its safety especially when used as a local anaesthetic in brachial plexus block.

Since the hemodynamic responses were similar, the study concludes that the ropivacaine-clonidine combination is also safer to use in brachial plexus block.

Hence the study showed that clonidine when added to local anaesthetic ropivacaine not only quickens the onset of the sensory and motor blockade but also increases the duration of postoperative analgesia and prolongs the time for the requirement for rescue analgesia. It has also been proven that the addition of clonidine to local anaesthetic prolongs the duration of action<sup>9</sup>. No adverse effects were reported in either of the groups in this study.

## CONCLUSION

Brachial plexus block provides a useful alternative to general anaesthesia for upper limb surgeries. The infraclavicular block is a method of accomplishing brachial plexus anaesthesia. Better accuracy and visualisation of the deposition of the drug are possible using ultrasound guidance. This technique not only helps in achieving the success rate to the maximum but also prolongs the duration of postoperative analgesia and reduces the risks and complications associated with general anaesthesia. This study demonstrated that  $\alpha_2$ -agonists like clonidine when added to ropivacaine in ultrasound-guided infraclavicular brachial plexus block not only reduce the onset of sensory & motor blockade but also prolong the duration of analgesia and reduce the

requirement of rescue analgesia. Thereby it suggests that it's an excellent mode of anaesthesia in patients undergoing surgeries in the upper limb.

## REFERENCES

1. Vikas Trehan, Uma Srivastava, Aditya Kumar, Surekha Saxena, Chandra Sekhar Singh, Ankit Darolia. Comparison of two approaches of infraclavicular brachial plexus block for orthopaedic surgery below mid-humerus. *Indian J Anaesthesia*. 2010; 54(3): 210–214.
2. MK Urban, B Urquhart ; Evaluation of brachial plexus anaesthesia for upper extremity surgery. *Regional Anesthesia*. 1994;19(3):175-82.
3. B Akerman, IB Hellberg ,C Trossvik .Primary evaluation of the local anesthetic properties of the amino amide agent ropivacaine. *Acta Anaesthesiol Scand*.1988; 32(7): 571-578.
4. Yadav RK, Sah BP, Kumar P, Singh SN. Effectiveness of addition of neostigmine or dexamethasone to local anesthetic in providing perioperative analgesia for brachial plexus block: A prospective, randomized, double blinded, controlled study. *Kathmandu University Medical Journal* 2008; 6(1): 302-309.
5. Qazi Ehsan Ali, L Manjunatha, Syed Hussain Amir. Efficacy of clonidine as an adjuvant to ropivacaine in supraclavicular brachial plexus block: A prospective study; *Indian J Anaesthesia*. 2014; 58(6): 709–713.
6. Alain Borgeat; Georgios Ekatodramis; Charles Dumont; An Evaluation of the Infraclavicular Block via a Modified Approach of the Raj Technique. *Anesth Analg*. 2001;93(2):436–41.
7. Klein SM, Evans H, Nielsen KC, Tucker MS, Warner DS, Steele SM. Peripheral nerve block techniques for ambulatory surgery. *Anesth Analg*.2005; 101(6): 1663-76.
8. Heid FM, Jage J, Guth M, Bauwe N, Brambrink AM.. Efficacy of vertical infraclavicular plexus block vs. modified axillary plexus block: a prospective, randomized, observer-blinded study. *Acta Anaesthesiol Scand*. 2005; 49(5): 677-82.
9. Wu TJ Lin SY; Liu CC; Chang HC; Lin CC; Ultrasound imaging aids infraclavicular brachial plexus block. *Ma Zui Xue Za Zhi*. 1993 Jun;31(2):83-6 .
10. Usha Bafna, Naresh Yadav, Mamta Khandelwal, Tuhin Mistry, CS Chatterjee, Rajeev Sharma. Comparison of 0.5% ropivacaine alone and in combination with clonidine in supraclavicular brachial plexus block. *Indian Journal of Pain*. 2015; 29(1); 41-45.